

Login Email

Password

CancerNetwork Members: [Login](#) | [Register](#)

[CancerNetwork](#) [SearchMedica](#) [Medline](#) [Drugs](#)

[Search](#)

Powered by [SearchMedica](#)

[PUBLICATIONS](#) [NEWS](#) [PODCASTS](#) [TOPICS](#) [BLOGS](#) [NURSES](#) [PATIENTS](#) [JOBS](#) [CONFERENCES](#) [CME](#) [SUPPLEMENTS](#)

[Home](#) » [Genitourinary Cancer](#) » [Renal Cell Carcinoma](#)

ONCOLOGY. Vol. 26 No. 6

[g+](#)

J'aime Soyez le premier de vos amis à indiquer que vous aimez ca.

Pages: [1](#) | [2](#)

[Next](#)

REVIEW ARTICLE

Integrating Innovative Therapeutic Strategies Into the Management of Renal Cell Carcinoma

By Janice P. Dutcher, MD^{1,2,3}, Waleed Fouad Mourad, MD, MS, PhD^{1,2,3,4}, Ronald D. Ennis, MD^{1,2,3,4} | June 20, 2012

¹Continuum Cancer Centers of New York, New York, New York ²St. Luke's-Roosevelt Hospital, New York, New York ³Beth Israel Medical Center, New York, New York ⁴Albert Einstein College of Medicine, Yeshiva University, Bronx, New York

[TOPIC INDEX](#)

ABSTRACT: Three emerging trends have occurred recently in renal cell carcinoma (RCC). First, over the last several decades there has been a marked increase in the diagnosis of RCC, with a corresponding decrease in the typical tumor size, resulting in an increased interest in less invasive approaches to primary tumor treatment. Second, while conventional radiotherapy plays a limited palliative role due to the relative radio-resistance of RCC, advances in immobilization and image guidance have led several investigators to consider stereotactic radiotherapy techniques (SRT) to overcome this resistance, with impressive results in the metastatic setting. In addition, preliminary use of SRT to treat the primary RCC tumor is underway. Thirdly, although RCC is resistant to conventional chemotherapy agents, exciting recent advances have emerged in the treatment of clear cell RCC, with the development of targeted agents in addition to immunotherapy-based treatments. In the current critical review we discuss these emerging trends in localized and systemic treatment as well as possible interesting combinations of the two modalities. Finally, we discuss the role of the new systemic agents in non-clear cell RCC.

- [Bone Metastases](#)
- [Breast Cancer](#)
- [CML](#)
- [Colorectal Cancer](#)
- [End-of-Life](#)
- [Ethics in Oncology](#)
- [GI Cancers](#)
- [GIST](#)
- [GU Cancers](#)
- [Gynecologic Cancers](#)
- [Head & Neck Cancer](#)
- [Hematology](#)
- [Leukemia](#)
- [Lung Cancer](#)
- [Lymphoma](#)
- [Melanoma](#)
- [Palliative Care](#)
- [Pancreatic Cancer](#)
- [Practice Management](#)
- [Practice & Policy](#)
- [Prostate Cancer](#)
- [RCC](#)
- [Sarcoma](#)
- [Triple-Negative Breast](#)

Introduction

Renal cell carcinoma, chromophobe cell type: The tumor cells vary from pale and transparent to acidophilic and granular.

In the United States, kidney cancer is the third most common genitourinary tumor and the seventh most common cancer.[1] The incidence of renal cell Carcinoma (RCC) has been increasing at a rate of 2% to 4% per year since 1975.[2] There has been a decrease in the size of tumors at diagnosis.

[More Topics](#)

which is likely due to increased use of abdominal imaging and higher incidental detection rates of asymptomatic tumors.[3] More than 80% of cancers of the kidney are adenocarcinoma, and another 10% are derived from the renal pelvis, a urothelial cancer related to bladder cancer and treated with bladder cancer regimens.

This discussion will focus on the nonurothelial carcinomas.

Standard Therapeutic Modalities in the Management of RCC Primary Tumors

Surgical treatment

Standard treatment for nonmetastatic RCC is complete resection of the tumor by either a radical or partial nephrectomy, which can be done as an open procedure or laparoscopically.[4-6] The relative merits of the various surgical approaches to management of RCC are beyond the scope of this review but are well summarized by Touijer et al.[7] Two randomized trials have shown that, in the context of receiving systemic interferon alfa or [interferon alfa-2b](#)([Drug information on interferon alfa-2b](#)), even many patients with metastatic disease should undergo nephrectomy, with reported survival benefits of 10 and 3 months in trials by the European Organisation for Research and Treatment of Cancer (EORTC) and the Southwest Oncology Group (SWOG), respectively.[8,9] Whether this benefit still applies in the context of current systemic therapies is uncertain.

Less invasive ablative modalities

Radiofrequency ablation (RFA), cryoablation (CA), and high-intensity focused ultrasound (HIFU) have been used as treatment options that are less invasive than radical or partial nephrectomy. RFA and CA are accomplished by introducing needle(s) or probe(s) into the tumor and delivering the ablative treatment. These procedures can be performed percutaneously, using image guidance to place the needles/probes, or they can be performed intraoperatively, usually via laparoscopic

surgery.[6,10] They usually are performed with the patient under conscious sedation or anesthesia, take about 2 to 3 hours, and often require an overnight stay in the hospital.

Gervais et al conducted a careful assessment of tumor response in a series of 100 RCC patients, with a mean follow-up of 2.3 years (range, 3.5 to 6 years). They reported achieving a tumor ablation rate of 90%. The most common complications were hemorrhage, occurring in 5% of patients, and ureteral stricture or injury, occurring in 3%; one-third of patients required a hospital admission of at least one night following the procedure. The same group of investigators reported on post-radiofrequency ablation syndrome, which consists of a low-grade fever and flu-like symptoms, and which has been shown to occur in approximately 30% of patients.[11]

TABLE 1



Treatment of RCC With Radiofrequency Ablation, Cryotherapy, and HIFU

Park et al reported on a prospective study of RFA in patients with RCC. A total of 94 tumors were treated in 78 patients. At a median follow-up of 25 months, the authors reported an initial RFA success rate of 98% and a recurrence-free rate of 97%. The rate of minor complications was 10% and that of major complications was 3%.[12]Percutaneous cryoablation of renal masses has been reported by Atwell et al in a retrospective series of 115 patients. Seventy-nine percent of these masses were biopsy-proven RCC or other malignancy; the other lesions were presumed malignant based on imaging. The authors reported a 100% local control rate in patients undergoing follow-up of 3 months or longer. However, local control was not defined in this paper. Six percent of patients experienced grade 3 toxicity, the most common being bleeding/hematoma, and 12% of patients required a hospitalization of two or more nights.[13] Although the results of RFA and cryotherapy are encouraging, the follow-up in most series is short, most of the studies are retrospective, and the procedures are still invasive. The only truly noninvasive modality is HIFU; however, this technique lacks a substantial evidence base, having been investigated mostly in small series of patients. Results of these modalities are summarized in [Table 1](#).

Stereotactic Radiosurgery (SRS) and Stereotactic Body Radiotherapy (SBRT) in Metastatic and Primary RCC

Deschavanne and Fertil reviewed the radiosensitivity of 694 cell lines in vitro. In their study, the cells were exposed to irradiation at doses up to 12 Gy and their response showed that RCC cells



SEARCH MEDICA RX

Browse drugs by name:

[A](#) [B](#) [C](#) [D](#) [E](#) [F](#) [G](#) [H](#) [I](#) [J](#)
[K](#) [L](#) [M](#) [N](#) [O](#) [P](#) [Q](#) [R](#) [S](#) [T](#)
[U](#) [V](#) [W](#) [X](#) [Y](#) [Z](#) [All](#)

Search for drugs:

FROM PHYSICIANS PRACTICE

[As a Physician, It's Great to Watch Medical Students Shine](#)

Jennifer Frank, MD, October 2, 2012

One of the sweet moments in teaching medical students or in parenting is seeing your student or child shine in their own right.

[Google Ads and Physicians: Get the Most for Your Money](#)

Simon Sikorski, MD, October 1, 2012

Based on consulting nearly 5,000 medical marketing campaigns over a decade, I can tell you that Google Ads alone are a complete waste of money.

[Working with Workers' Compensation Medical Billing Codes](#)

P.J. Cloud-Moulds, September 29, 2012

When reimbursements are low for your workers' compensation patients, it may not be the payers' fault. Here's how to make sure you are paid what you deserve.

[Preparing Your Medical Practice for a HIPAA Audit](#)

Daniel M. Lindenberg, September 28, 2012

Here's a breakdown of the federal government's HIPAA audit procedures and how your office can be prepared.

[Upcoding: Is Your EHR Putting You at Risk?](#)

Karen Zupko, September 26, 2012

As anti-fraud efforts step up, there's little doubt that the OIG will be looking at your practice. Make sure your patient records accurately reflect physician services.

were the most radiation-resistant cells.[14] The clinical results of standard fractionated radiotherapy (RT) for RCC mimic this in vitro work with relatively poor results. For example, results of several studies of whole-brain radiotherapy (WBRT) for brain metastases from RCC have been poor, showing a median survival after WBRT of only 2 to 4.4 months.[15-18] A poor outcome is seen even in patients with a good recursive partitioning analysis class who receive higher radiation doses. [17,18]

TABLE 2



Results of Conventional and Stereotactic Radiotherapy for Treatment of Brain Metastases of RCC

Compared with reported results of standard fractionated RT, the techniques of SRS and SBRT have demonstrated good responses in an experimental animal model and in clinical studies of patients with RCC.[19] A prospective trial was conducted by Hoshi et al involving 42 patients with brain metastases from RCC who underwent Gamma Knife (Elekta, Stockholm, Sweden) radiosurgery (GKS). Twenty of the 42 cases had multiple brain metastases. Neurological symptoms, seen in 40 patients, were rapidly improved in 80% of these patients after GKS. MRI evaluation after GKS in 32 patients showed the disappearance of brain tumor in 28%. The median survival time was 12.5 months, with an overall local control (LC) rate of 80%.[20] Several retrospective studies have shown similar findings ([Table 2](#)).

TABLE 3



Results of Standard Radiotherapy and SBRT for Metastatic RCC to Extracranial Sites

Similar improved results with SBRT compared to conventional treatment are also seen for other metastatic sites. DiBiase et al reported results of palliative RT using standard fractionation in 114 patients and showed a 50% pain relief rate.[21] On the other hand, others have shown significantly better response rates and excellent LC rates with SBRT. In a prospective study of 30 patients with 82 lesions (metastatic and inoperable primary RCC) who underwent SBRT at doses of 8 Gy × 4, 10 Gy × 4, 15 Gy × 2, or 15 Gy × 3, after a median follow-up of 52 months, local progression was seen in only 2% of patients.[22] Results of standard and SBRT treatment of extracranial sites are summarized in [Table 3](#).

TABLE 4



Results of Stereotactic Radiotherapy Techniques for Treatment of Primary RCC Tumors

With these encouraging results in the metastatic setting, treatment of the primary renal tumor with SBRT is beginning. The only prospective therapeutic trial has recently been reported by Kaplan et al. This prospective phase I dose-escalation study of SRS for primary RCC used CyberKnife (Accuray, Sunnyvale, California) and gold fiducials for image guidance in medically inoperable patients. The dose-level range (21, 28, 32, or 39 Gy) was delivered in three fractions. Tumors up to 5 cm in diameter were included. The investigators reported minimal toxicity; only two patients with chronic renal failure had worsening of their renal function during follow-up. Only one patient treated at a dose of 21 Gy developed local progression.[23] These results, along with results of other retrospective series, are summarized in [Table 4](#). SBRT should continue to be studied prospectively and may play an important role in management of RCC in the future.

Immunotherapy

Immunotherapy with interferon alfa and interleukin-2 has been used for treatment of metastatic clear cell RCC (mRCC) for more than 20 years and is currently the only treatment for this disease that has the potential for a durable complete response (CR).[24-28]

Both interferon alfa and interleukin-2 are components of innate and adaptive immune responses, and function to alter biologic pathways. Interferon alfa modulates a number of proteins, and is noted for its activation of dendritic cells. It also has antiproliferative effects on hematopoietic cells and potentially direct effects on tumor cells.[29] Interleukin-2 was previously named T-cell growth factor, and its major initial effect is expansion and activation of populations of tumor-directed killer cells, along with a cascade of pro-inflammatory cytokines. Clinically it is administered in supra-physiologic doses in an attempt to activate killer cells and overwhelm the tumor-induced

MOST POPULAR

- [Most Popular](#)
- [Most Emailed](#)
- [Most Recent](#)
- [Fluid Complications](#)
- [USPSTF Says No Screening for Ovarian Cancer in New Guidelines](#)
- [New Approaches for Triple-Negative Breast Cancer](#)
- [Head and Neck Tumors](#)
- [Chest Wall Tumor Discovered in 12-Year-Old Girl](#)
- [Smoking Marijuana Linked to Increased Risk of Testicular Cancer](#)
- [FDA Approves Enzalutamide \(Xtandi\) for Late-Stage Prostate Cancer](#)
- [New Approaches for Triple-Negative Breast Cancer](#)
- [Adjuvant Therapy of Breast Cancer in Women 70 Years of Age and Older: Tough Decisions, High Stakes](#)
- [Long-Term Effects of Chemo on the Cognitive Function of Cancer Patients](#)
- [ESMO: New Agents, ODM-201 and Tasquinimod, Show Activity in Prostate Cancer](#)
- [Asymptomatic 57-Year-Old Man Undergoes Prostate Biopsy](#)
- [ESMO: BRAF/MEK Inhibitor Combo Bests Monotherapy for Metastatic Melanoma](#)
- [ESMO: New Agent, Aldoxorubicin \(INNO-206\), Shows Activity in Soft-Tissue Sarcoma](#)
- [A 58-Year-Old Woman Develops a Pruritic, Erythematous Plaque Involving the Areola](#)

[Click here to subscribe to our newsletter](#)

COMMENTS

- [Most Commented](#)
- [Most Recent](#)
- [Smoking Marijuana Linked to Increased Risk of Testicular Cancer](#)
- [The Natural History of Hormone Receptor-Positive Breast Cancer: Attempting to Decipher an Intriguing Concept](#)
- [Diabetes in Childhood Cancer Survivors Linked to Radiation of Pancreas](#)
- [FDA Approves Bosutinib \(Bosulif\) for Chronic Myeloid Leukemia \(CML\)](#)
- [Using Social Media in Oncology for Education and Patient Engagement](#)

immunosuppressive component of the immune system (regulatory T cells and immunosuppressive cytokines). The utilization of these treatments has been limited by the complexity and intensity of treatment, requiring specialized centers to administer this therapy. Nevertheless, with an outcome that includes decades-long response, interleukin-2 remains in the armamentarium for mRCC.

Recent reports of new immunotherapeutic agents have aroused interest once again in immunotherapy for cancer. One such agent, ipilimumab (Yervoy), is an anti-CTLA-4 monoclonal antibody reported to have activity in mRCC.[30] This agent removes the “brake” from immune activation, leading to an anti-tumor response and auto-immune adverse events.[31,32] The degree and durability of its anti-tumor activity in RCC is still undergoing evaluation. In addition, the PD-1/PD-L (programmed death-1/programmed death-1 ligand) pathway is being investigated because it is directed toward reversing the immunosuppression that tumors are able to induce. This pathway regulates T-cell activation as a mechanism for down-regulation of cytotoxic lymphocytes in the tumor environment, allowing tumor evasion of host immunity.[31]

Radiation and immunotherapy

There has been long-standing interest among radiation biologists in the potential for radiation to induce immune responses. Studies have demonstrated induction of inflammatory cytokines (such as tumor necrosis factor, interleukin-1, and type I interferon[32-34]) and alteration in expression of major histocompatibility (MHC) antigens from exposure to radiation, and thus potential for activation of cellular immunity.[35,36] Clinical studies are needed to assess the role of a combination of immune modulators and RT in patients with cancers such as RCC, in which the immune system plays an important antitumor role.

Pages: **1** [2](#)

[Next](#)



J'aime Soyez le premier de vos amis à indiquer que vous aimez ca.

Join the Conversation

Want to join the conversation? If you're a healthcare professional, we'd like to hear your comments. Just [sign in](#) or [register today](#) to become part of our growing, online community.

Email me when someone comments on this article.

Submit

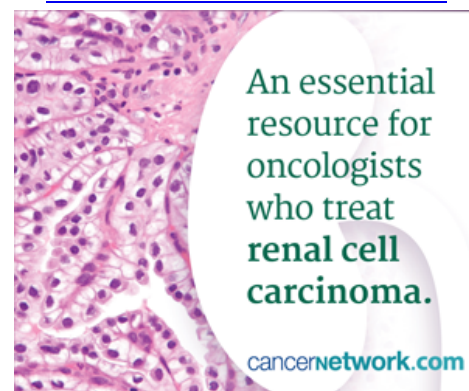
This article reviewed

[A Urologic Perspective on Management of Localized and Metastatic RCC](#)

[Integration of Newer Strategies Into the Management of RCC](#)

- [What Are My Responsibilities to Inform?](#)
- [Am I Obligated to Give Therapy Against My Better Judgment?](#)
- [The Natural History of Hormone Receptor-Positive Breast Cancer: Attempting to Decipher an Intriguing Concept](#)
- [Using Social Media in Oncology for Education and Patient Engagement](#)
- [USPSTF Says No Screening for Ovarian Cancer in New Guidelines](#)

[Click here to subscribe to our newsletter](#)



SearchMedica Search Result

Find peer-reviewed literature and websites for practicing medical professionals

- [CME on Rcc](#)
- [Evidence on Rcc](#)
- [Guidelines on Rcc](#)
- [Patient Education on Rcc](#)
- [Clinical Trials on Rcc](#)
- [Practical Articles on Rcc](#)

[Research and Reviews on Rcc](#)
[All "Rcc" results](#)

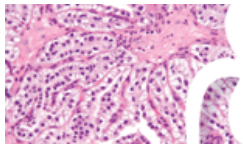




- Practical clinical reviews
- Editorial features
- Expert commentaries
- New, interactive features

CLICK HERE
to learn more

[CancerNetwork](#) on Facebook



cancernetwork.com

An essential resource for oncologists who treat **renal cell carcinoma**.

[CancerNetwork](#) | [ConsultantLive](#) | [Diagnostic Imaging](#) | [Musculoskeletal Network](#) | [OBGYN.net](#) | [PediatricsConsultantLive](#) | [Physicians Practice](#) | [Psychiatric Times](#) | [SearchMedica](#) | [Medical Resources](#)



UBM

© 1996 - 2012 [UBM Medica LLC](#), a [UBM](#) company

[Privacy Statement](#) - [Terms of Service](#) - [Advertising Information](#) - [Editorial Policy Statement](#) - [UBM Medica Network Privacy Policy](#)